

Review

Open Access

Photodynamic therapy in the therapy for recurrent/persistent nasopharyngeal cancer

Maarten AM Wildeman*, Heike J Nyst, Baris Karakullukcu and Bing I Tan*

Address: Department of Head and Neck Oncology and Surgery, The Netherlands Cancer Institute - Antoni van Leeuwenhoek Hospital, Plesmanlaan 121, 1066 CX Amsterdam, the Netherlands

Email: Maarten AM Wildeman* - m.wildeman@nki.nl; Heike J Nyst - h.nyst@nki.nl; Baris Karakullukcu - h.karakullukcu@nki.nl; Bing I Tan* - i.tan@nki.nl

* Corresponding authors

Published: 17 December 2009

Received: 2 October 2009

Head & Neck Oncology 2009, 1:40 doi:10.1186/1758-3284-1-40

Accepted: 17 December 2009

This article is available from: <http://www.headandneckoncology.org/content/1/1/40>

© 2009 Wildeman et al; licensee BioMed Central Ltd.

This is an Open Access article distributed under the terms of the Creative Commons Attribution License (<http://creativecommons.org/licenses/by/2.0>), which permits unrestricted use, distribution, and reproduction in any medium, provided the original work is properly cited.

Abstract

To determine the efficacy of Photodynamic therapy of patients with recurrent Nasopharyngeal Carcinoma we reviewed all available literature.

Since the treatment options for recurrent or persistent Nasopharyngeal Carcinoma are limited, the survival rates poor and the complications severe; there is definitely a place for alternative treatment modalities with more efficacy and less morbidity. Photodynamic therapy (PDT) has the potential to be a very effective local treatment modality for recurrent or persistent nasopharyngeal cancer, without the severe side effects seen with re-irradiation. This review shows all reported results of Photodynamic therapy in the treatment for Nasopharyngeal Carcinoma.

Introduction

Nasopharyngeal carcinoma (NPC) occurs sporadically in the Western world, but is endemic in certain parts of South-East Asia, such as southern China and the Indonesian archipelago [1]. The worldwide incidence of NPC exceeds 80.000 cases/year with 19,616 new cases each year in South-China [2], but for most developing countries data are lacking due to absent or inadequate registries.

Treatment for primary NPC is radiotherapy, with chemotherapy for advanced stage disease. Despite the radiotherapy responsiveness of nasopharyngeal tumours, good long term survival is only achieved for patients who have early primary tumours with minimal neck disease with 67-71% 10 years disease free survival for T1, T2 and N0-1. Survival is poor for patients who have extended tumours

and/or extended neck nodes 29-54% 10 years disease free survival for T3, T4 and N2, N3 [3-6].

Poor survival in the T4N0-1 category is chiefly the result of the high local recurrence rate (63.8%), where as for the T1-2N2-3 category, it is the result of the high distant metastases rate (approximately 50%). For the local recurrent or persistent tumours there are few treatment options left all with severe side effects.

Re-treatment of recurrent/persistent NPC

Usual treatment options for early stage recurrent or persistent NPC are surgery in combination with external radiotherapy, brachytherapy alone [7-9], or in combination with external re-irradiation [10-13] or stereotactic radiotherapy [14]. The standard treatment for advanced stages of recurrent or persistent disease is chemotherapy fol-

lowed by re-irradiation, or concomitant chemo-re-irradiation [15]. Pryzant reported on 53 patients with locally persistent or recurrent NPC treated with re-irradiation. Forty-two patients were re-treated with external beam therapy alone and 11 with a component of brachytherapy. Local recurrence was confined to the nasopharynx in 27 patients, and persistent tumour in 26 patients. The five-year actuarial local tumour control rate was 35%, five-year disease free survival was 18%, and overall survival was 21%. Eight Patients developed severe complications from retreatment, two involving the brain, one the spinal cord, and two the cranial nerves, all of which were fatal. The five-year actuarial incidence of severe complications was 17%. The incidence of severe complications was related to the total cumulative dose of external irradiation [16].

Lee described the incidence of late complications after re-irradiation in 891 patients with local recurrence after definitive radiation therapy for nasopharyngeal carcinoma. After external re-irradiation, brachytherapy or a combination of both, a wide variety of serious complications, such as temporal lobe necrosis, cranial neuropathy, endocrine dysfunction, trismus and bone/soft tissue necrosis was reported, with an overall incidence of 23 to 29% and a treatment mortality from 1 to 3% [17]. Other authors also report these serious side effects [10-12]. A major determinant of post-treatment complication is the severity of damage sustained during the initial course. In case of re-irradiation after an interval of 2 years or more, the sum of total doses tolerated is higher than predicted based on results of single course irradiations [18].

Since the treatment options for recurrent or persistent NPC are limited, the survival rates poor and the complications severe; there is definitely a place for alternative treatment modalities with more efficacy and less morbidity.

Photodynamic Therapy

Photodynamic therapy (PDT) is a non-invasive treatment modality that might have a substantial role in treatment of recurrent nasopharyngeal carcinoma. PDT facilitates tumour destruction by the combination of a photosensitizer and laser light of a specific wavelength.

The therapeutic response of PDT depends on a complex combination of parameters that includes drug dose, drug-light interval, tissue oxygenation, light dose and light intensity (the last two are more accurately referred to as fluence and fluence rate, respectively). PDT works through non thermal chemical pathways to damage cancer cells. The main agents of cell destruction are activated singlet oxygens. The cancer cells are destroyed by a process that might take up to several weeks and the treated area heals with normal mucosa advancing from adjacent tissue much like radiation treatment.

Photodynamic Therapy for Recurrent and Persistent NPC

Sun [19] has published the largest case series with 137 patients. Unfortunately this article is in Chinese. He has treated 137 NPC patients with hematoporphyrin derivative mediated PDT. Forty-eight and 72 hours after iv administration of 3-5 mg/kg HpD, laser treatment with either argon or dye laser was carried out. Dye laser (630 nm) with over 350 mw output transmitted through quartz fiber was given to 57 patients. Argon laser (488 nm and 514.5 nm) was delivered to 80 patients. The results were: complete response 76 cases (55.47%) and marked response 47 cases (34.31%), with an over-all marked response rate of 89.78% (123/137). These results are very successful. However, it is not clear if the patients had recurrent NPC or PDT is delivered as primary first choice treatment. In either case the results are very encouraging with such a large case series.

Kulapaditharom [20] et al reported in 1996 five patients treated with PDT for recurrent or residual NPC in Ramathidoni hospital in Bangkok. Three of these patients had a T1 tumour with no lymph node involvement and no distant metastasis. Two of these patients had a T3 tumour with no lymph node involvement and no distant metastases. 48 hours before illumination patients received Hematoporphyrin derivative with a dosage of 3 mg/kg and were illuminated (630 nm) by an optical fiber. The dose varied within 50-100 J/cm². Power of the laser beam was adjusted to give a density within 100-150 mW/cm² to avoid thermal effect.

The T1 tumour patients had a complete response after one treatment. Complete response has been suggested by endoscopic examination and negative biopsy. The duration of response were: 24, 16 and 11 months. The T3 tumours responded partially. One patient received 4 treatments and the other one 2 treatments before they switched to chemotherapy. The partial response duration was respectively 19 and 12 months.

The side effects described for all treatment were oedema, pain and photosensitivity. All side effects would solve without treatment. There was one patient with severe pain after PDT. All other side effects were mild and moderate.

The same Kulapaditharom [21] et al reported in 2000 the treatment of 12 NPC patients. The patients received Hematoporphyrin derivative with a dosage of 3 mg/kg 48 hours before they were illuminated (630 nm) by a flat cut optical fiber (with a core diameter of 400 µm, Laser-scope California) with a with a dose of 100 J/cm² and a fluence rate of 100 mW/cm².

One patient was primary treated for an unknown primary. The primary tumour revealed in the nasopharynx (T1 NO

MO) and because this patient already received radiotherapy and neck dissection he was treated with PDT. Complete response as observed for a follow up period of 31 months.

Six patients were treated for recurrent or residual T1-T2 NPC without lymph nodes and distant metastasis. These patients had received chemo-radiation for initial treatment. All patients had a biopsy and endoscopic complete response after PDT treatment. Duration response was between 10 and 66 months, mean duration was 26.5 months. One patient died 12 months after PDT cause of an unrelated cause.

One patient had a residual T3N0M0 adenoid cystic carcinoma instead of squamous cell carcinoma. Patient was treated with PDT and surgery. Patient had a partial response and has been symptom free for 22 months.

Four patients received PDT as adjunct to conventional treatment; these patients were all T3-T4 patients. One received radiotherapy, the other three received 6 cycles of chemotherapy. Three patients had a partial response and one had a complete response.

Tong [22] et al reported 12 patients treated with PDT for recurrent NPC in Prince of Wales Hospital in Hong Kong. These patients were treated with hematoporphyrin derivative 5 mg/kg and exposed with 200 J/cm² delivered from a gold laser vapor with a wave length of 630 nm.

In eight patients cure of disease was deemed possible. The other four patients were treated for palliation of nasal obstruction. Four patients received surgical debulking before PDT. All patients showed radiology confirmed tumour regression six months after treatment. From the eight patients treated for cure five patients had a residual disease after 3-5 months, the other three remained disease free with a follow up between 9-12 months. Four patients had nasal regurgitation and two patients had their trismus aggravated, these side effects were temporarily. Two patients had mild skin hypersensitivity.

Lofgren [23] et al reported 5 patients treated with PDT for recurrent or persistent NPC in Orebro Medical Center Hospital, Sweden. Four patients were treated with hematoporphyrin derivative 2.5 mg/kg. One patient has been treated with porfimer sodium 2.0 mg/kg. The light dose varied from 50 to 100 J/cm² and radiance varied from 100 to 150 mW/cm².

Four patients had SCC, two of them had a recurrence and two of them persistent disease. One patient had a persistent adenocarcinoma. All patients were initially treated with radiotherapy.

Three patients remain tumour free with a follow up between 51 and 60 months. These patients had a tumour depth of 10 mm or less. One patient had persistent disease after PDT, a MRI-scan showed after treatment a tumour depth of 13 mm. One patient had a recurrence 6 months after treatment.

All patients had significant headache (3 to 8 months) and middle ear effusion. Two patients experienced minor problems of photosensitivity after sun exposure five 40 days after treatment (Additional file 1).

Discussion

PDT has the potential to be a very effective local treatment modality for NPC, without the severe side effects seen with radiotherapy.

The articles above have shown that PDT is effective in destroying NPC, with good local control of tumor growth and complete responses in the majority of small recurrent or persistent disease (T1, T2) and long-term palliation in advanced stage (T3, T4) of the recurrence.

There are several advantages of PDT for management of recurrent NPC. Perhaps the most important advantage is its repeatability. PDT does not have cumulative effects. In case of a partial response the same area can be illuminated again. Secondly PDT is a local treatment rather than a systemic one. The photosensitizing drug accumulates in higher concentrations within cancer cells rendering them more susceptible to the toxic effects of light, compared to normal healthy cells and the light is delivered directly onto the tumour sparing the surrounding normal mucosa. Two other advantages of PDT are normal healing of the wound and illumination is only once.

In the papers reviewed above they all used the first generation photosensitizer hematoporphyrin. Yow [24] et al has shown in nasopharyngeal cancer cell lines that the uptake of second generation photosensitizer temoporfin is higher and efficiency is better compared with hematoporphyrin. Yow [25] et al also compared temoporfin and merocyanine 540, both second generation photosensitizers. They concluded that temoporfin-mediated PDT has a more potent effect in comparison with merocyanine-540-mediated PDT. Based on these studies we hope for even better treatment results if temoporfin is used.

Illumination of nasopharyngeal cavity is a challenge, since access is difficult and the cavity has a complex and irregular geometry. Furthermore the cavity varies significantly in size and geometry between patients. The complex shape of the nasopharyngeal cavity makes it impossible to produce a homogenous field of illumination. In order to deliver a sufficient light distribution

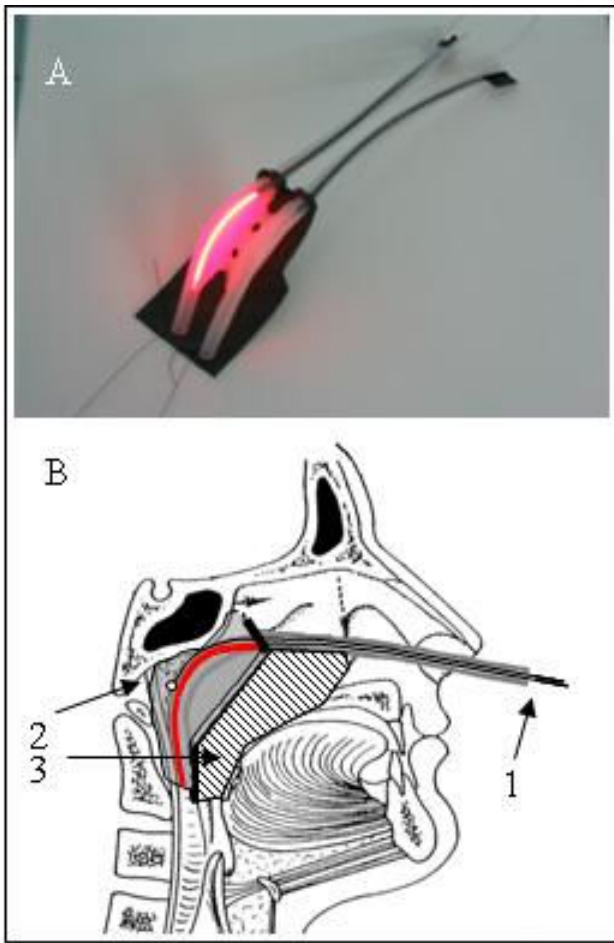


Figure 1
A: Nasopharynx applicator, B: schematic view of positioning and illumination. 1. Cylindrical diffuser in shielding tube. 2. Target area. 3. Soft palate is shielded. Figure 1 have been used previously by Nyst et al, 2007 [26]

throughout the nasopharyngeal cavity over exposure cannot be avoided. Over exposure of tumour or surrounding normal mucosa is however not considered a problem. Some critical structures are well protected by bone others; however, like the soft palate and the dorsal oropharyngeal wall would suffer unacceptable damage by this approach. Hence, these areas must be shielded against the laser light. For this purpose we have developed a novel dedicated light delivery applicator that ensures proper light delivery to the target area and enables for proper shielding of the risk areas [26,27]. A new study has been commenced to use this applicator to deliver PDT to patients with recurrent NPC cancers by our group. How we illuminate the Nasopharynx is shown by Figure 1, 2, 3.

The side effects are much less frequent and severe compared to chemotherapy. Sunlight exposure have shown

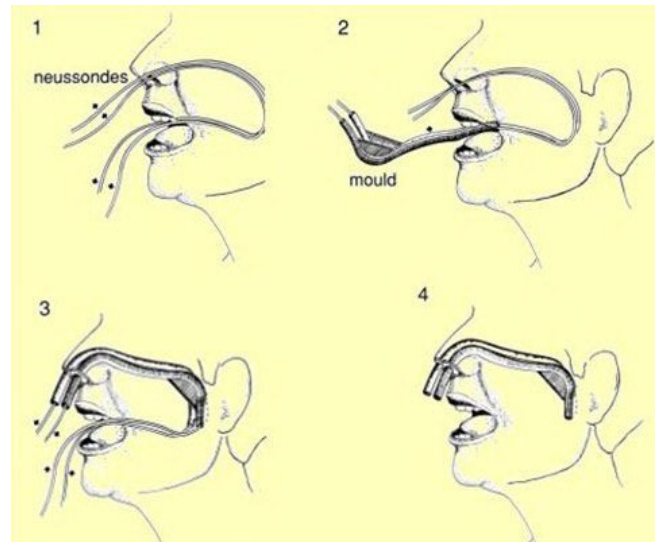


Figure 2
Insertion of the Nasopharyngeal Applicator.

that photosensitivity is not a real burden for these patients and only limited adverse events were related to this problem [28]. In general, patients in this part of the world have a colored skin that makes them less prone to sunburn. The fact that people in the tropics generally avoid sun exposure also helps to minimize the problems around the photosensitivity.

The immunologic reaction followed by PDT could be partly responsible for the good results. The theory is that an immunological response will be provoked by the use of PDT [29]. So in addition to these clinical trials several groups are working on the effectiveness of PDT in laboratory settings. PDT and the use of natural compounds become one of the new approaches in the investigation of NPC treatment. Such a group from Singapore has reported very encouraging results with hypericin mediated PDT. This group has published extensively on biochemical pathways of cell damage caused by hypericin-PDT on NPC cell lines in vitro. Their excellent review titled "Hypericin lights up the way for the potential treatment of nasopharyngeal cancer by photodynamic therapy" by Olivo [30] et al summarizes this effort and proposes that hypericin-PDT is a potential treatment of NPC in humans. Koon [31] et al has chosen a different photosensitizing agent from the traditional Chinese medicine: curcumin. Their in vitro study with CNE2 NPC cells shows it to be a promising agent.

Xu et al[32] preferred to work with photodynamic effects of pyropheophorbide-a methyl ester (MPPa) in CNE2 NPC cells, demonstrating the apoptotic effect and suggesting its clinical potential. Mak et al[33] worked with

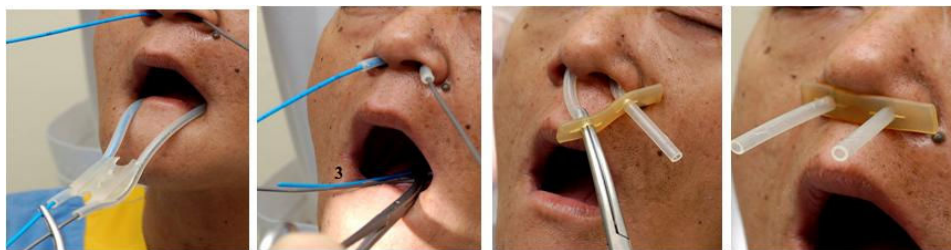

Figure 3
Volunteer with Nasopharyngeal Applicator.

the same cell line inducing phototoxicity with sulfonamide derivatives of porphycene with successful results. Betz [34] et al obtained good results in their in vitro study with amore conventional photosensitizer: 5-aminolevulinic acid.

Bae [35] et al examined the immunotherapeutic significance of HPV-immortalized tumour cell lysates induced by PDT and CpG-oligodeoxynucleotide(ODN). They found a significant induced IFN- β production and cytotoxic T- cell response in the PDT-cell lysate plus ODN immunized groups. Although PDT in combination with immunotherapy is still in experimental fase it offers a great promise as a new alternative treatment. On to this time no research has been done on PDT in combination with Immunotherapy in EBV related NPC. This combination could be very promising not only for local recurrence but also for advanced disease.

Competing interests

The authors declare that they have no competing interests.

Authors' contributions

MW did the literature search and wrote the article, HN and BK both repeated literature search and helped writing the introduction and discussion. IT designed overall article. All authors read and approved the final manuscript.

Author information

Prof. Tan is also connected to Amsterdam Medical Center, as such his alternative email address is i.b.tan@amc.uva.nl

Additional material

Additional file 1

Overall Treatment Results

Click here for file

[<http://www.biomedcentral.com/content/supplementary/1758-3284-1-40-S1.DOC>]

Acknowledgements

The authors greatly appreciate the cooperation of H.J. Sterenborg and R.L. van Veen from Erasmus Medical Center with their help on the pictures and animations.

References

1. Devi BC, Pisani P, Tang TS, Parkin DM: **High incidence of nasopharyngeal carcinoma in native people of Sarawak, Borneo Island.** *Cancer Epidemiol Biomarkers Prev* 2004, **13**:482-486.
2. Parkin DM, Bray F, Ferlay J, Pisani P: **Global cancer statistics.** *CA Cancer J Clin* 2005, **55**:74-108.
3. Lee AW, Poon YF, Foo W, Law SC, Cheung FK, Chan DK, Tung SY, Thaw M, Ho JH: **Retrospective analysis of 5037 patients with nasopharyngeal carcinoma treated during 1976-1985: overall survival and patterns of failure.** *Int J Radiat Oncol Biol Phys* 1992, **23**:261-270.
4. Moench HC, Phillips TL: **Carcinoma of the nasopharynx. Review of 146 patients with emphasis on radiation dose and time factors.** *Am J Surg* 1972, **124**:515-518.
5. Chien CR, Chen SW, Hsieh CY, Liang JA, Yang SN, Huang CY, Lin FJ: **Retrospective comparison of the AJCC 5th edition classification for nasopharyngeal carcinoma with the AJCC 4th edition: an experience in Taiwan.** *Jpn J Clin Oncol* 2001, **31**:363-369.
6. Kajanti MJ, Mantyla MJ: **Carcinoma of the nasopharynx. A retrospective analysis of treatment results in 125 patients.** *Acta Oncol* 1990, **29**:611-614.
7. Law SC, Lam WK, Ng MF, Au SK, Mak WT, Lau WH: **Reirradiation of nasopharyngeal carcinoma with intracavitary mold brachytherapy: an effective means of local salvage.** *Int J Radiat Oncol Biol Phys* 2002, **54**:1095-1113.
8. Kwong DL, Wei WI, Cheng AC, Choy DT, Lo AT, Wu PM, Sham JS: **Long term results of radioactive gold grain implantation for the treatment of persistent and recurrent nasopharyngeal carcinoma.** *Cancer* 2001, **91**:1105-1113.
9. Leung TW, Tung SY, Sze WK, Sze WM, Wong VY, Wong CS, SK O: **Salvage radiation therapy for locally recurrent nasopharyngeal carcinoma.** *Int J Radiat Oncol Biol Phys* 2000, **48**:1331-1338.
10. Leung TW, Tung SY, Sze WK, Sze WM, Wong VY, SK O: **Salvage brachytherapy for patients with locally persistent nasopharyngeal carcinoma.** *Int J Radiat Oncol Biol Phys* 2000, **47**:405-412.
11. Teo PM, Kwan WH, Chan AT, Lee WY, King WW, Mok CO: **How successful is high-dose (> or = 60 Gy) reirradiation using mainly external beams in salvaging local failures of nasopharyngeal carcinoma?** *Int J Radiat Oncol Biol Phys* 1998, **40**:897-913.
12. Lee AW, Foo W, Law SC, Poon YF, Sze WM, SK O, Tung SY, Chappell R, Lau WH, Ho JH: **Recurrent nasopharyngeal carcinoma: the puzzles of long latency.** *Int J Radiat Oncol Biol Phys* 1999, **44**:149-156.
13. Hwang JM, Fu KK, Phillips TL: **Results and prognostic factors in the retreatment of locally recurrent nasopharyngeal carcinoma.** *Int J Radiat Oncol Biol Phys* 1998, **41**:1099-1111.
14. Chua DT, Sham JS, Kwong PW, Hung KN, Leung LH: **Linear accelerator-based stereotactic radiosurgery for limited, locally persistent, and recurrent nasopharyngeal carcinoma: effi-**

- cacy and complications.** *Int J Radiat Oncol Biol Phys* 2003, **56**:177-183.
15. Al Sarraf M, Reddy MS: **Nasopharyngeal carcinoma.** *Curr Treat Options Oncol* 2002, **3**:21-32.
 16. Pryzant RM, Wendt CD, Delclos L, Peters LJ: **Re-treatment of nasopharyngeal carcinoma in 53 patients.** *Int J Radiat Oncol Biol Phys* 1992, **22**:941-947.
 17. Lee AW, Law SC, Foo W, Poon YF, Cheung FK, Chan DK, Tung SY, Thaw M, Ho JH: **Retrospective analysis of patients with nasopharyngeal carcinoma treated during 1976-1985: survival after local recurrence.** *Int J Radiat Oncol Biol Phys* 1993, **26**:773-782.
 18. Lee AW, Foo W, Law SC, Peters LJ, Poon YF, Chappell R, Sze WM, Tung SY, Lau WH, Ho JH: **Total biological effect on late reactive tissues following reirradiation for recurrent nasopharyngeal carcinoma.** *Int J Radiat Oncol Biol Phys* 2000, **46**:865-872.
 19. Sun ZQ: **[Photodynamic therapy of nasopharyngeal carcinoma by argon or dye laser--an analysis of 137 cases].** *Zhonghua Zhong Liu Za Zhi* 1992, **14**:290-292.
 20. Kulapaditharom B, Boonkitticharoen V: **Photodynamic therapy in the treatment of head and neck cancers: a two-year experience.** *J Med Assoc Thai* 1996, **79**:229-235.
 21. Kulapaditharom B, Boonkitticharoen V: **Photodynamic therapy in management of head and neck cancers and precancerous lesions.** *J Med Assoc Thai* 2000, **83**:249-258.
 22. Tong MC, van Hasselt CA, Woo JK: **Preliminary results of photodynamic therapy for recurrent nasopharyngeal carcinoma.** *Eur Arch Otorhinolaryngol* 1996, **253**:189-192.
 23. Lofgren LA, Hallgren S, Nilsson E, Westerborn A, Nilsson C, Reizenstein J: **Photodynamic therapy for recurrent nasopharyngeal cancer.** *Arch Otolaryngol Head Neck Surg* 1995, **121**:997-1002.
 24. Yow CM, Chen JY, Mak NK, Cheung NH, Leung AW: **Cellular uptake, subcellular localization and photodamaging effect of temoporfin (mTHPC) in nasopharyngeal carcinoma cells: comparison with hematoporphyrin derivative.** *Cancer Lett* 2000, **157**:123-131.
 25. Yow CM, Mak NK, Szeto S, Chen JY, Lee YL, Cheung NH, Huang DP, Leung AW: **Photocytotoxic and DNA damaging effect of temoporfin (mTHPC) and merocyanine 540 (MC540) on nasopharyngeal carcinoma cell.** *Toxicol Lett* 2000, **115**:53-61.
 26. Nyst HJ, van Veen RL, Tan IB, Peters R, Spaniol S, Robinson DJ, Stewart FA, Levendag PC, Sterenborg HJ: **Performance of a dedicated light delivery and dosimetry device for photodynamic therapy of nasopharyngeal carcinoma: phantom and volunteer experiments.** *Lasers Surg Med* 2007, **39**:647-653.
 27. van Veen RL, Nyst H, Rai Indrasari S, Adham Yudharto M, Robinson DJ, Tan IB, Meewis C, Peters R, Spaniol S, Stewart FA, et al.: **In vivo fluence rate measurements during Foscan-mediated photodynamic therapy of persistent and recurrent nasopharyngeal carcinomas using a dedicated light applicator.** *J Biomed Opt* 2006, **11**:041107.
 28. D'Cruz AK, Robinson MH, Biel MA: **mTHPC-mediated photodynamic therapy in patients with advanced, incurable head and neck cancer: a multicenter study of 128 patients.** *Head Neck* 2004, **26**:232-240.
 29. Korbelik M, Sun J, Cecic I, Serrano K: **Adjuvant treatment for complement activation increases the effectiveness of photodynamic therapy of solid tumors.** *Photochem Photobiol Sci* 2004, **3**:812-816.
 30. Olivo M, Du HY, Bay BH: **Hypericin lights up the way for the potential treatment of nasopharyngeal cancer by photodynamic therapy.** *Curr Clin Pharmacol* 2006, **1**:217-222.
 31. Koon H, Leung AW, Yue KK, Mak NK: **Photodynamic effect of curcumin on NPC/CNE2 cells.** *J Environ Pathol Toxicol Oncol* 2006, **25**:205-215.
 32. Xu CS, Leung AW: **Photodynamic effects of pyropheophorbide-a methyl ester in nasopharyngeal carcinoma cells.** *Med Sci Monit* 2006, **12**:BR257-BR262.
 33. Mak NK, Kok TW, Wong RN, Lam SW, Lau YK, Leung WN, Cheung NH, Huang DP, Yeung LL, Chang CK: **Photodynamic activities of sulfonamide derivatives of porphycene on nasopharyngeal carcinoma cells.** *J Biomed Sci* 2003, **10**:418-429.
 34. Betz CS, Lai JP, Xiang W, Janda P, Heinrich P, Stepp H, Baumgartner R, Leung A: **In vitro photodynamic therapy of nasopharyngeal carcinoma using 5-aminolevulinic acid.** *Photochem Photobiol Sci* 2002, **1**:315-319.
 35. Bae SM, Kim YW, Kwak SY, Kim YW, Ro DY, Shin JC, Park CH, Han SJ, Oh CH, Kim CK, et al.: **Photodynamic therapy-generated tumor cell lysates with CpG-oligodeoxynucleotide enhance immunotherapy efficacy in human papillomavirus 16 (E6/E7) immortalized tumor cells.** *Cancer Sci* 2007, **98**:747-752.

Publish with **BioMed Central** and every scientist can read your work free of charge

"BioMed Central will be the most significant development for disseminating the results of biomedical research in our lifetime."

Sir Paul Nurse, Cancer Research UK

Your research papers will be:

- available free of charge to the entire biomedical community
- peer reviewed and published immediately upon acceptance
- cited in PubMed and archived on PubMed Central
- yours — you keep the copyright

Submit your manuscript here:
http://www.biomedcentral.com/info/publishing_adv.asp

